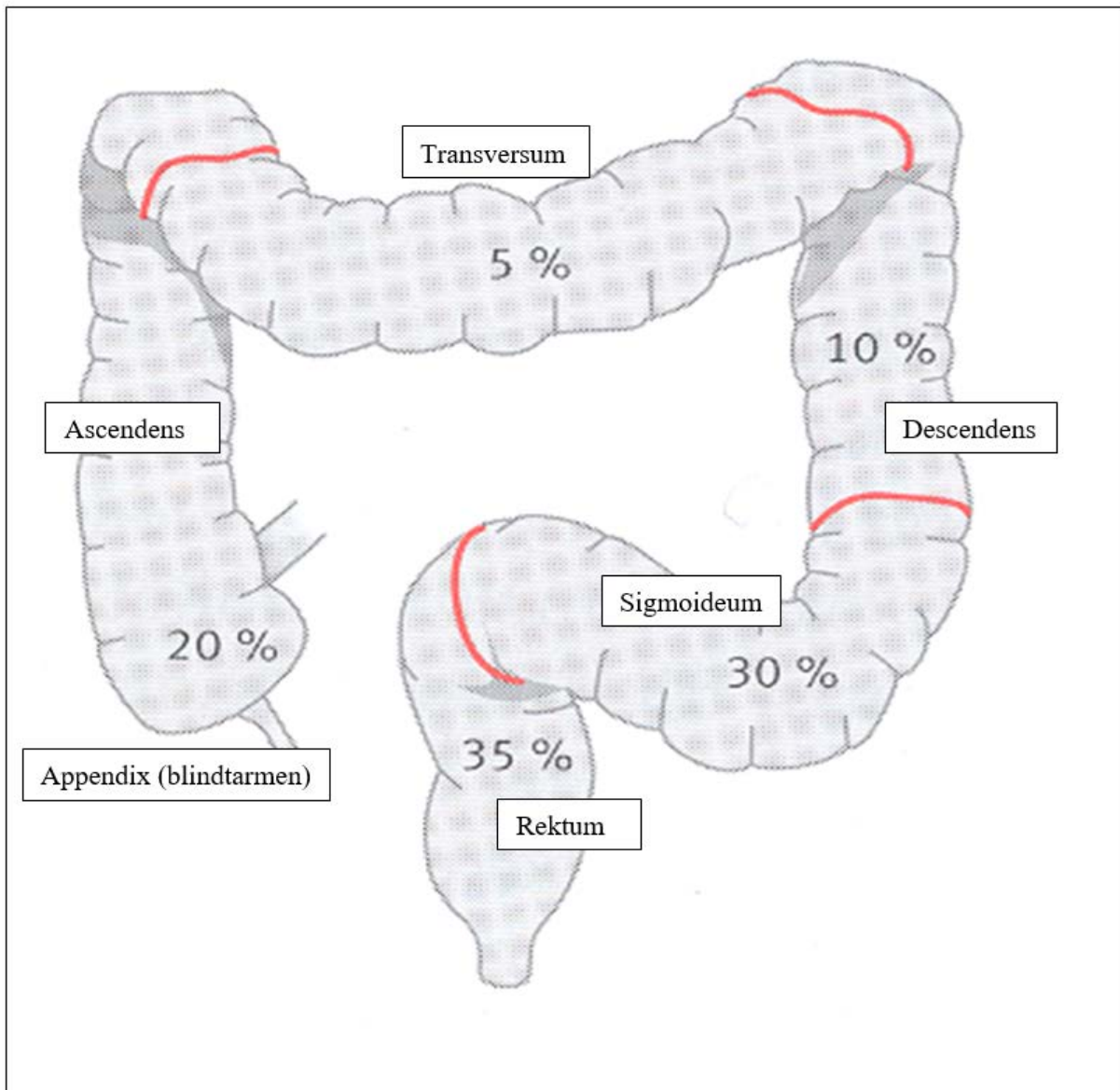
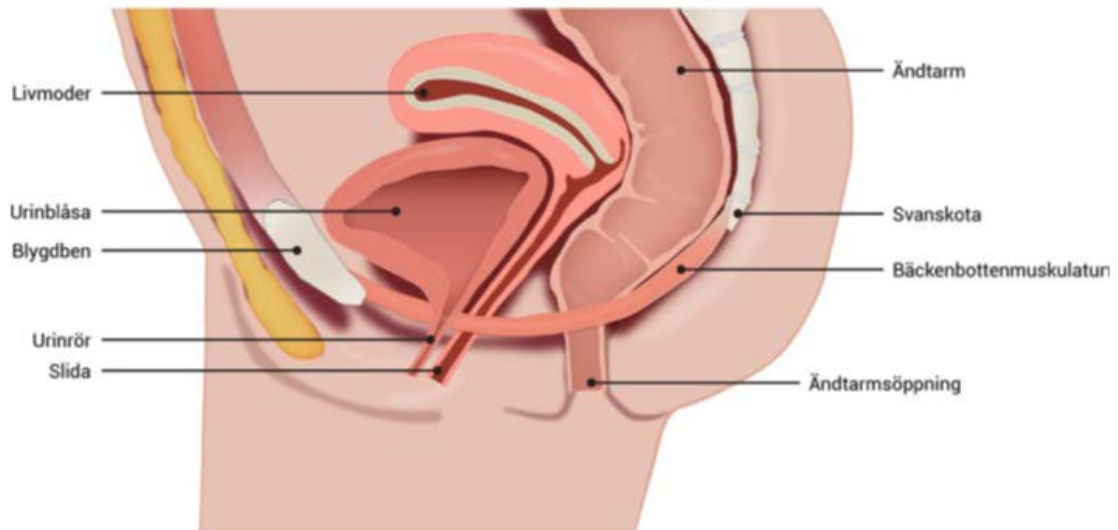
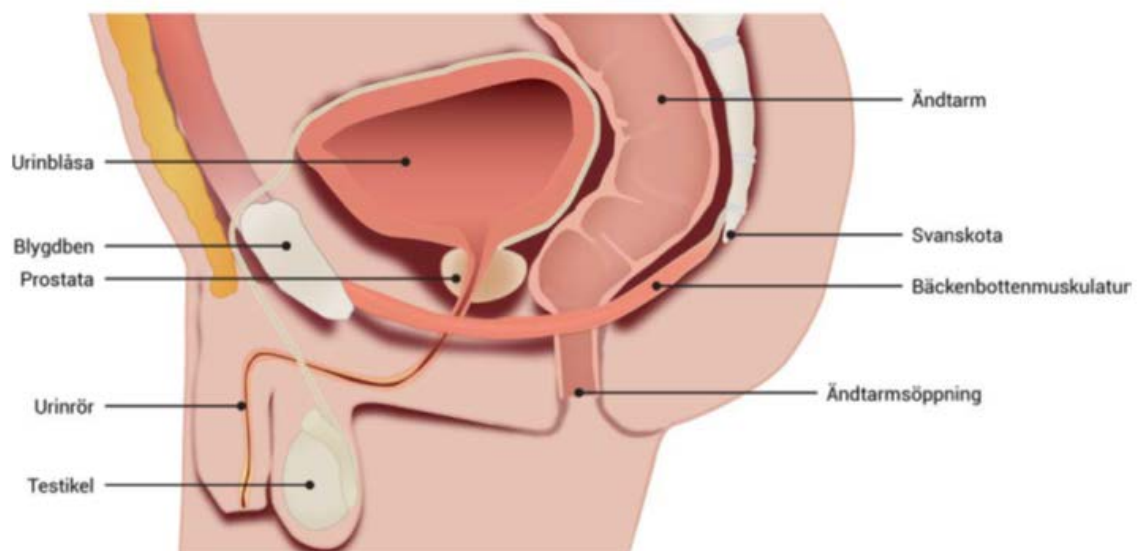


Min diagnos- tumörens placering ändtarm





Bäckenbotten i genomskärning, kvinna. Bild framtagen av RCC Stockholm Gotland



Bäckenbotten i genomskärning, man. Bild framtagen av RCC Stockholm Gotland.